

# Morgellons Disease: A Chemical and Light Microscopic Study

Marianne J. Middelveen<sup>1</sup>, Elizabeth H. Rasmussen<sup>2</sup>, Douglas G. Kahn<sup>3</sup> and Raphael B. Stricker<sup>1\*</sup>

<sup>1</sup>International Lyme and Associated Diseases Society, Bethesda, MD

<sup>2</sup>College of Health Sciences, University of Wyoming, Laramie, WY

<sup>3</sup>Department of Pathology, Olive View - UCLA Medical Center, Sylmar, California

## Abstract

Morgellons disease is an emerging multisystem illness characterized by unexplained dermopathy and unusual skin-associated filament production. Despite evidence demonstrating that an infectious process is involved and that lesions are not self-inflicted, many medical practitioners continue to claim that this illness is delusional. We present relevant clinical observations combined with chemical and light microscopic studies of material collected from three patients with Morgellons disease. Our study demonstrates that Morgellons disease is not delusional and that skin lesions with unusual fibers are not self-inflicted or psychogenic. We provide chemical, light microscopic and immunohistological evidence that filaments associated with this condition originate from human epithelial cells, supporting the hypothesis that the fibers are composed of keratin and are products of keratinocytes.

**Keywords:** Morgellons disease; Digital dermatitis; Lyme disease; *Borrelia burgdorferi*; Spirochetes; Keratin

## Introduction

Morgellons disease (MD) is an emerging dermatological disorder and multisystem illness. The disease is characterized by unexplained dermopathy associated with formation of unusual filaments found both subcutaneously and emerging from spontaneously appearing, slow-healing skin lesions [1]. Filaments associated with MD appear beneath unbroken skin [1,2], thus demonstrating that they are not self-planted. Filaments have been observed protruding from and attached to a matrix of epithelial cells [3]. This finding demonstrates that the filaments are of human cellular origin and are not textile fibers. These filaments have not been matched with known textile fibers, and dye-extracting solvents have failed to release coloration; the fibers are also very strong and heat resistant [4,5]. MD filaments are physically and chemically consistent with keratin, a biofiber produced in the epithelium by keratinocytes. A recent report from the Centers for Disease Control and Prevention (CDC) confirmed that these filaments have a protein composition that is consistent with keratin [6].

Lyme disease-like symptoms in MD such as neurological disorders and joint pain are evidence of systemic involvement [1,2,7]. Objective clinical evidence of disease has been demonstrated by its association with peripheral neuropathy, delayed capillary refill, decreased body temperature, tachycardia, elevated pro-inflammatory markers, cytokine release, selective immune deficiency and elevated insulin levels, suggesting that an infectious process is involved [8,9]. Patients may demonstrate abnormal laboratory findings indicative of low-grade anemia, endocrine dysfunction, immune dysfunction and inflammation [8,10]. Patients with MD are predominantly sero-reactive to *Borrelia burgdorferi* (Bb) antigens, suggesting a likelihood of Lyme borreliosis or related spirochetal infection [1,10]. Patients also demonstrate a higher than expected percentage of positive laboratory findings for other tick-borne diseases, suggesting the possible involvement of coinfecting pathogens [10].

The observation of unusual filaments forming in lesions is not unique to humans afflicted with MD. Similarities between MD and bovine digital dermatitis (BDD) have been described [3]. BDD is an emerging disease afflicting cattle and is characteristically associated with unusual filament formation in skin above the hooves [11]. Late-stage proliferative lesions demonstrate elongation of keratinocytes,

hyperkeratosis, and proliferation of long keratin filaments [12-14]. Consistent detection of spirochetes associated with lesions is evidence of spirochetal etiologic involvement [15-20]. Experimental induction of lesions with tissue homogenates [21] and pure cultured treponemes [22] supports a role for spirochetes as primary etiologic agents.

Like BDD, MD is associated with apparent spirochetal infection and unusual filament production [3]. A comparison between BDD and MD suggests that the unusual fibers seen in MD patients may result from hyperkeratosis and filament production as described in BDD. It appears that MD fibers are likewise composed of keratin produced by keratinocytes, a phenomenon that has been demonstrated in BDD [3]. The following three case studies provide further evidence supporting this hypothesis.

## Materials and Methods

### Human and bovine samples

Three patients meeting the clinical criteria for Morgellons disease collected calluses, scabs, filaments, and other dermatological debris and submitted the material for microscopic examination. The collected samples were examined by bright-field microscopy at 100x magnification. Specimens were illuminated either superior or posterior to the specimen. Some specimens were also illuminated with ultraviolet (UV) light.

Biopsies from cattle with BDD were kindly provided by Dr. Dorte Dopfer, Faculty of Veterinary Medicine, University of Wisconsin, Madison, WI. Biopsy material from proliferative late stage BDD was examined for comparison to MD samples with 8x magnification under

**\*Corresponding author:** Raphael B. Stricker, M.D., 450 Sutter Street, Suite 1504, San Francisco, CA 94108, USA, Tel: (415)399-1035; Fax: (415) 399-1057; E-mail: [rstricker@usmamed.com](mailto:rstricker@usmamed.com)

**Received** January 27, 2012; **Accepted** March 12, 2012; **Published** March 16, 2012

**Citation:** Middelveen MJ, Rasmussen EH, Kahn DG, Stricker RB (2012) Morgellons Disease: A Chemical and Light Microscopic Study. J Clin Exp Dermatol Res 3:140. doi:10.4172/2155-9554.1000140

**Copyright:** © 2012 Middelveen MJ, et al. This is an open-access article distributed under the terms of the Creative Commons Attribution License, which permits unrestricted use, distribution, and reproduction in any medium, provided the original author and source are credited.

a dissecting microscope. This material was also tested for fluorescence under UV light.

For the chemical experiments, samples of normal hair, filaments from Cases 1 and 2 and BDD fibers were studied for reactivity to three caustic agents: sodium hypochlorite 12%, sodium hydroxide 10%, and potassium hydroxide 10%. Each sample was suspended in 150  $\mu$ l of the chemical solution for up to two hours, and serial light microscopy was performed at 0, 1, 10, 30, 60 and 120 minutes. Dissolution of fibers was assessed by fraying, loss of shape and/or disintegration at each timepoint.

For the immunohistological experiments, filament samples from Cases 1 and 2 were stained for keratin using monoclonal antibodies. Briefly, formalin-fixed paraffin-embedded filaments were incubated with monoclonal antibodies AE1/AE3 (Dako North America Inc, Carpinteria, CA) and AE5/AE6 (Cell Marque Corporation, Rocklin, CA) directed against cytokeratins 1/3 and 5/6, respectively, using the Envision<sup>+</sup> Dual-Link System-HRP (Dako) according to the manufacturer's instructions. The samples were stained using a horseradish peroxidase label, and the brown staining of keratin was visualized under light microscopy.

## Clinical Observations

### Case 1

The patient is a 72-year-old grandmother and former fashion model who developed painful lesions on her hands while working in her garden in San Antonio, Texas, in 1994. The lesions were punctate with ragged edges and healed slowly, leaving visible scarring. Fibers were observed in the lesions and under intact skin on her hands using a 60x handheld microscope. Topical steroids had no effect. The patient also noted the onset of fatigue, joint pain and muscle aches, and systemic steroid treatment exacerbated these symptoms without any improvement in the skin lesions. Medical evaluation was negative for autoimmune or infectious diseases, and neuropsychiatric evaluation was entirely normal. Biopsy of a lesion demonstrated hyperkeratosis and parakeratosis with no visible organisms or evidence of vasculitis. However "textile fibers" were noted in the dermal layer of the biopsy specimen.

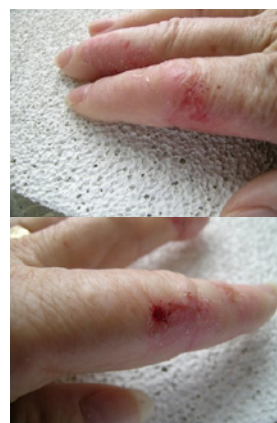In 2001, after numerous visits to dermatologists and other medical specialists and treatment with topical emollients and anti-inflammatory medications, the patient had persistent skin lesions on her hands, fatigue and musculoskeletal pain. Despite the use of gloves to avoid scratching, her lesions persisted and she was unable to work in her garden or hold her grandchildren due to pain in her hands and joints. She recalled numerous tickbites but never saw an erythema migrans (EM) rash, and she was found to have positive testing for *B. burgdorferi*, *Babesia microti* and *Bartonella henselae*. She was treated with antimicrobial medications and her fatigue and musculoskeletal pain improved significantly. However her skin lesions persisted. She received anti-parasitic medication, and the lesions improved to the point that she could once again do gardening. The lesions persist but are "manageable" (Figure 1A).

### Case 2

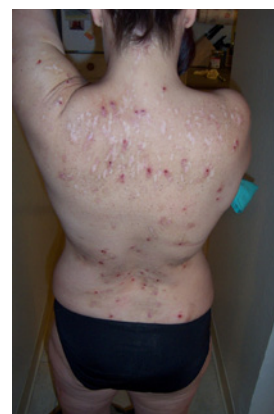The patient is a 49-year-old registered nurse who had numerous tickbites while hiking, camping and horseback riding in Missouri, Texas and Northern California over more than a decade. She never saw an EM rash. In 1997 while living in San Francisco she developed painful lesions on her face, trunk and extremities. The lesions were

punctate with ragged edges. Some lesions healed slowly, leaving visible scarring, while others did not heal at all, and fibers that were resistant to extraction were observed within several lesions. Fibers were also observed under intact skin using a 60x handheld microscope. Topical steroids had no effect. Biopsy of a lesion on her leg revealed hyperkeratosis and parakeratosis without evidence of infection or vasculitis. However, "textile fibers" were noted in the dermal layer of the biopsy specimen. She also developed fatigue and musculoskeletal pain, and systemic steroid treatment exacerbated these symptoms without any improvement in the skin lesions. Medical evaluation was negative for autoimmune or infectious diseases, and neuropsychiatric evaluation was completely normal.

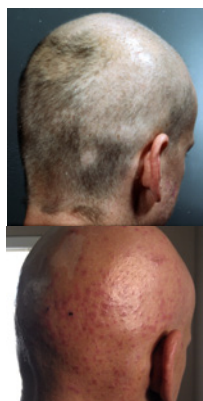Because of persistent fatigue, musculoskeletal pain and her history of tick exposure, the patient was evaluated for Lyme disease in 2004 and had positive testing for *B. burgdorferi* and *Ehrlichia chafeensis*. Antibiotic therapy led to improvement in the fatigue and musculoskeletal pain, but the skin lesions persisted. She received anti-parasitic medication and her skin lesions improved somewhat, but new lesions appeared and healing lesions caused painful scarring. She has received intermittent courses of antibiotics over the past six years, and her skin lesions continue to wax and wane (Figure 1B).



**Figure 1A:** Lesions on hands of Case 1 following extensive antimicrobial treatment. Note erythematous base with ragged edges.



**Figure 1B:** Lesions on back of Case 2. Note punctate appearance of open lesions and scarred appearance after healing. Lesions occur in locations that could not be easily reached by the patient.



**Figure 1C:** Head of Case 3 photographed at disease onset in 2002 (top) and during disease flare in 2011 (bottom). Note punctate lesions with ragged edges in bottom picture. Patient shaved his head in effort to decrease pain from scalp lesions.

### Case 3

The patient is a 47-year-old business manager who was in excellent health until he developed a “bullseye” rash, fever, chills, severe headache, musculoskeletal pain and malaise after hiking in the woods near Atlanta, Georgia, in 1995. He had pulled ticks off his dog, which also became ill at the same time. He was diagnosed with fibromyalgia and treated with pain medications, but by 2000 he had become progressively disabled by muscle pain and fatigue. In 2002 he developed crawling sensations on his head, face, groin and other body areas where there was hair. The sensations were accompanied by painful skin lesions. He was diagnosed with folliculitis and put on a topical antibiotic, which made his skin symptoms worse. He began to notice painful fibers coming out of the skin on his face, head and other hirsute areas, and he could not sleep because the fibers were so painful. He extracted fibers from his facial lesions, but new ones appeared. He was diagnosed with trichotillomania and delusional parasitosis.

He went to several dermatologists and was treated with topical lindane and oral cephalexin without benefit. Treatment with oral ketoconazole and fluconazole provided marginal improvement in the crawling sensations and skin lesions. A scalp biopsy demonstrated increased numbers of catagen and telogen follicles with fragmented hair fibers and inner root sheath consistent with trichotillomania. There were no visible organisms or evidence of vasculitis. Medical evaluation was negative for autoimmune or infectious diseases, and neuropsychiatric evaluation revealed reactive depression. He was treated with antidepressants without benefit. Finally in 2005 a physician noted fibers under his skin using a 60x hand-held microscope. Testing for Lyme disease was indeterminate in 2006, and treatment with doxycycline was given for one month without benefit. The patient continues to suffer from crawling sensations, skin lesions, musculoskeletal pain, disabling fatigue and depression. He is reluctant to see any more physicians about his skin condition (Figure 1C).

## Results

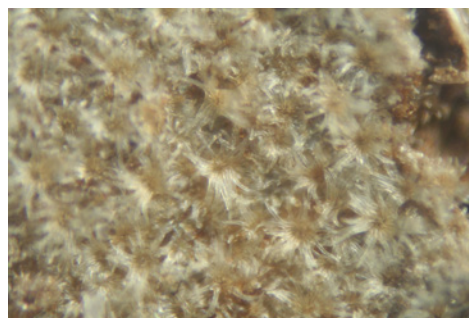
### MD Microscopic observations

**Case 1:** Microscopic examination revealed a wide range of filaments in various stages of formation ranging from early stages that demonstrated either single or clusters of hyaline, tentacle-like projections with tapered ends (tentacle diameter approximately 5


$\mu\text{m}$ ) to macroscopic masses or mats of tangled fibers (approximately 1 mm diameter) (Figures 2A-2H). Floral-like formations of early-stage filaments were observed in some samples that were collected on different dates and years (Figure 2A). These structures had tapered ends with bases originating at a central point and were found in groups anchored to a dried dermal matrix. The reverse side of some of these specimens revealed a layer of pavement epithelial cells (Figure 2B). Epithelial matrices anchoring longer hyaline fibers were observed, suggesting that as the tentacle-like projections increase in length individual fibers may become tangled, or clumped (Figure 2C). Various structures composed of clumps, strings, and nest-like balls of hyaline filaments were observed and some of these were glued together by clotted or dried exudate (Figure 2D). This suggests that tangled filaments may eventually separate from the supporting epithelial matrix and form balls and other tangled structures.

Some samples revealed raised unidentified papules protruding from dried epithelial tissue that might be abnormal hair follicles. Long isolated colored filaments, filament fragments, balls, and clumps of fibers (red, blue, black and green) were also observed, but were not attached to or growing from epithelial tissue. Many of these colored filaments had bulb-like ends (50  $\mu\text{m}$  diameter) that looked very much like those found in hair follicles (Figure 2E).

Many fibers displayed iridescence under bright-field microscopy and were fluorescent under UV lighting. Hyaline or white fibers fluoresced brightly, as did blue fibers (Figure 2F). Red and green fibers displayed striking iridescence (Figure 2G, Figure 2H) but fluoresced with less intensity than the blue and white fibers. This suggests that melanin pigments may be associated with red and green filaments. Early floral-shaped clusters were brightly fluorescent. Human hair




**Figure 2A:** Fibers from Case 1. Note floral appearance of fibers (100x magnification).



**Figure 2B:** Pavement epithelium on underside of floral fibers shown in Figure 2A (100x magnification).

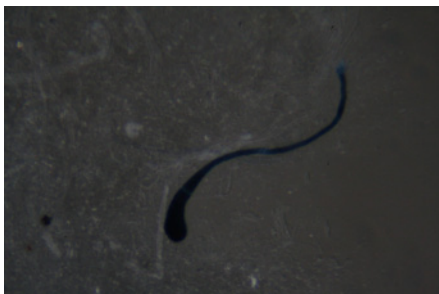



**Figure 2C:** Hyaline fibers forming macroscopic masses in finger webbing from Case 1 (50x magnification).



**Figure 2D:** Clumps of hyaline filaments surrounding clotted or dried exudate from Case 1 (100x magnification).



**Figure 2E:** Blue filament with bulb-like end (50 µm diameter) similar to a hair follicle from Case 1 (100x magnification).

was not fluorescent nor was normal skin. Color intensity and hue of the red and blue filaments was influenced by the color spectrum of the illuminating light. This property and the presence of iridescence suggests that a structural component is involved in the unusual colors seen in Morgellons fibers.

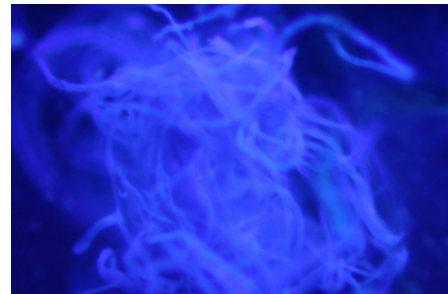
**Case 2:** Microscopic examination of scab material revealed scab detritus imbedded with long filaments of various colors (Figures 3A-3D). Hyaline, red, blue, and light purple fibers were observed (10-40 µm diameter) (Figure 3A, Figure 3B). One sample revealed fibers tangled around a hair and these fibers may have been associated with the hair follicle (Figure 3C). Smaller, pale purple fibers (10 µm diameter) appeared to form a mesh around the follicle. Some samples revealed fibers that lay beneath or penetrated dermal tissue Figure 3D.

**Case 3:** Microscopic examination was performed with particular attention to hair follicles, as the patient had reported unusual

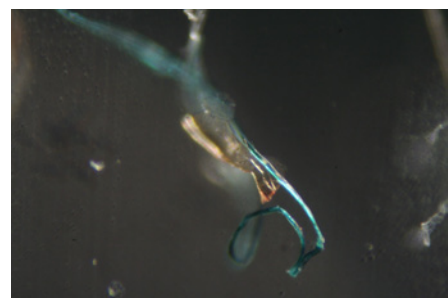
filament formation associated with the follicles. Microscopy revealed abnormalities of the follicular bulbs and the hair associated with these follicles that indicated abnormal functioning of follicular keratinocytes (Figures 4A-4D). Many follicles contained malformed bulbs with distorted shapes, and some follicles had two or more hairs branching from a single inner root sheath (Figure 4A). Filaments stemming from the bulb end were found in some follicles and these appeared as root-like growths (Figure 4B). Transparent filaments were observed that stemmed from cells within the inner root sheath (Figure 4C). On some hairs red or blue colored filaments branched from the shaft (Figure 4D). Many hairs were flattened or tape-like on cross-section rather than concentric. These hairs were similar in appearance to Morgellons filaments.

### BDD Microscopic observations


Biopsies from late proliferative stage BDD lesions were examined microscopically for comparison (Figures 5A-5D). Although the scale of filaments was much larger, the BDD filaments (roughly ten times




**Figure 2F:** Bluish fluorescence of fibers under UV lighting from Case 1 (100x magnification).




**Figure 2G:** Iridescence of a green fiber from Case 1 (100x magnification).




**Figure 2H:** Striking iridescence of a red fiber from Case 1 (100x magnification).



**Figure 3A:** Red and blue fibers in skin samples from Case 2 (100x magnification).



**Figure 3B:** Red and blue fibers embedded in skin from Case 2 (100x magnification).



**Figure 3C:** Fibers tangled around a hair (larger black shaft to right of figure) in Case 2 (100x magnification).

larger) were similar in appearance compared to the specimens observed in Case 1 (Figure 5A, Figure 5B). Filaments were macroscopic, opaque and dirty white in color, ranging in size from less than 0.5 mm in diameter to about 1 mm in diameter. In cross section filaments appeared to originate beneath the stratum corneum (Figure 5C). Longer filaments were close to 1 mm in length. The BDD filaments demonstrated fluorescence under UV light (Figure 5D).

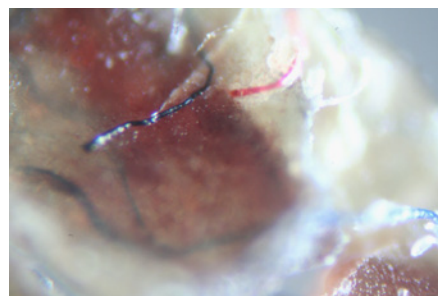
### Chemical Experiments

Samples of normal hair, colored filaments and dermal material from Cases 1 and 2, and BDD fibers were subjected to immersion in caustic agents. Duplicate experiments with each caustic agent were performed on each sample. Results of the experiments are shown in (Table 1) Normal hair and patient filaments began to fray after incubation for 1 minute, and the patient filaments had completely disintegrated after incubation for 120 minutes in 12% sodium hypochlorite. Normal hair

was still visible at this timepoint. In contrast, patient filaments began to fray at 1 minute in 10% sodium hydroxide but were still visible after 120 minutes, similar to normal hair. The hair and patient filaments were more resistant to 10% potassium hydroxide, with visible fraying beginning at 10 minutes and fibers still visible at 120 minutes. Although the larger BDD fibers appeared to be more resistant to the chemicals, fraying and shape change similar to the human samples was evident at 120 minutes with each caustic agent.

### Keratin immunostaining

The results of keratin immunostaining experiments are shown in Figure 6. The MD filaments from Case 1 stained strongly with the “pankeratin” antibody AE1/AE3 directed against cytokeratin 1/3. In contrast, the filaments stained weakly with the more restrictive antibody AE5/AE6 directed against cytokeratin 5/6. Staining with AE1/AE3 was seen over the length of the fiber, while staining with AE5/



**Figure 3D:** Fibers penetrating dermal tissue from Case 2 (100x magnification).

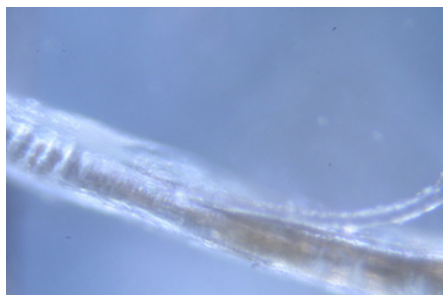

**Figure 4A:** Hair follicle from Case 3 showing two hairs branching from a single inner root sheath (100x magnification).




**Figure 4B:** Hair follicle from Case 3 showing filaments stemming from bulb end (100x magnification).

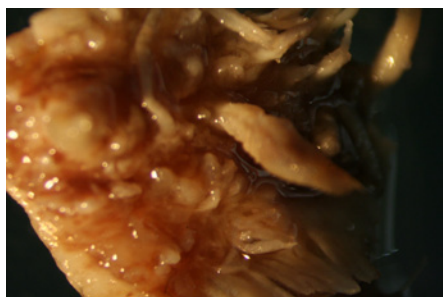




**Figure 4C:** Hair follicle from Case 3 showing transparent filaments stemming from the inner root sheath (100x magnification).



**Figure 4D:** Hair follicle from Case 3 showing blue fiber (top) and red fiber (bottom) branching from the hair shaft (left, 100x magnification; right, 200x magnification).



**Figure 5A:** Bovine digital dermatitis (BDD) sample showing coarse fibers (8x magnification).

AE6 was only detected in the outermost scale. Melanin pigmentation was not seen in the fibers. No staining was detected with an irrelevant monoclonal antibody, and similar positive keratin staining with AE1/AE3 was detected in MD fibers from Case 2 (data not shown).

## Discussion

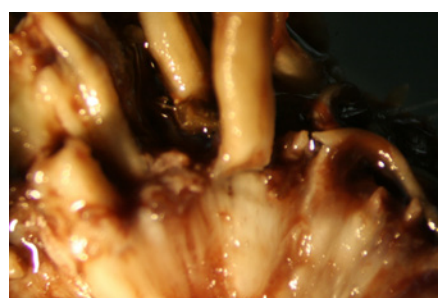
Our three patients had features of MD that are commonly described in the medical literature, including insidious onset, dermatological signs and systemic symptoms, lack of response to immunosuppressive treatment and association with tickborne diseases [1-3]. Case 1 had skin lesions confined to the hands (Figure 1A), while Cases 2 and 3 had disseminated skin lesions over the head, trunk and extremities (Figures 1B and 1C). In addition, Case 3 had symptoms associated primarily with hair follicles, and a sensation of change in hair composition and

texture is often reported by Morgellons patients [1,10]. These MD patterns have been recognized in prior studies [1,2] and we propose a classification of localized MD versus disseminated MD based on the distribution of the dermatopathy. Although the reason for this dermatopathy distribution is unknown, the location of skin lesions may be related to the cell of origin of the fibers seen in lesions or under the skin, as discussed below. Further study of the dermatopathy distribution in MD is warranted.

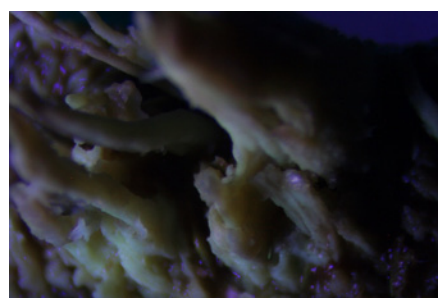The present study demonstrates Morgellons filaments that clearly originate from a layer of pavement epithelial cells visibly held together by desmosomes (Figure 2). The predominant cells found in pavement epithelial tissue are keratinocytes. We also noted MD fibers that clearly originate from the inner root sheaths of hair follicles (Figures 2-4), and keratinocytes are the predominant cell type in this tissue. Keratinocytes produce the biofiber keratin. A cross section of BDD filaments likewise demonstrates filament origin from cells beneath the stratum corneum



**Figure 5B:** BDD sample showing floral fibers (8x magnification). Note similarity to MD floral fibers from Case 1 (Figure 2A).



**Figure 5C:** Cross section of BDD sample showing coarse fibers that originate beneath the stratum corneum (8x magnification).

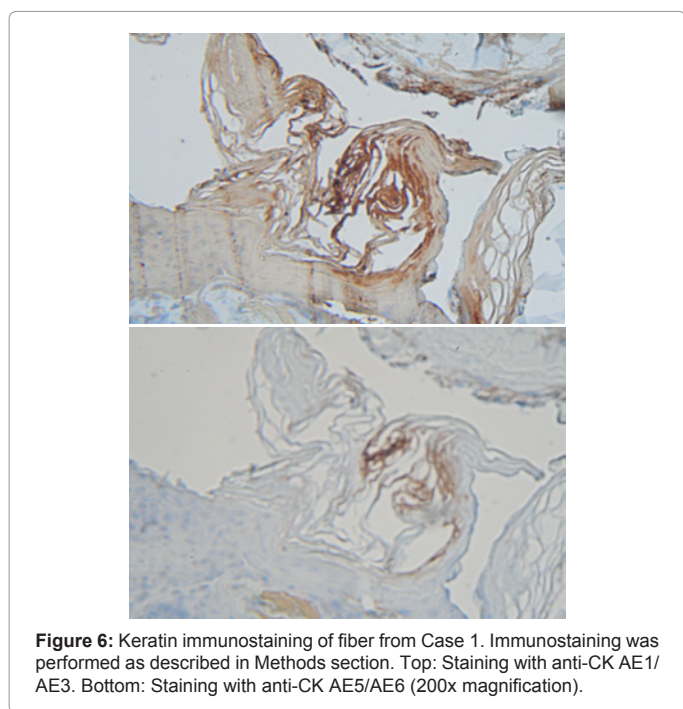


**Figure 5D:** BDD sample showing coarse fibers with fluorescence under UV lighting (8x magnification).

Incubation with:	Time (minutes)	Case 1 Fiber Dissolution	Case 2 Fiber Dissolution	BDD fiber Dissolution	Human hair Dissolution
NaOCl 12%	1	±	±	±	±
	10	±	±	±	±
	60	+	+	±	±
	120	+	+	±	±
NaOH 10%	1	±	±	-	±
	10	±	±	±	±
	60	±	±	±	±
	120	±	±	±	±
KOH 10%	1	-	-	-	-
	10	±	±	-	±
	60	±	±	-	±
	120	±	±	±	±

NaOCl, sodium hypochlorite; NaOH, sodium hydroxide; KOH, potassium hydroxide. (-) indicates no fiber dissolution, (±) indicates partial fiber dissolution, (+) indicates complete fiber dissolution.

**Table 1:** Dissolution of Morgellons filaments and BDD fibers in caustic reagents.



**Figure 6:** Keratin immunostaining of fiber from Case 1. Immunostaining was performed as described in Methods section. Top: Staining with anti-CK AE1/AE3. Bottom: Staining with anti-CK AE5/AE6 (200x magnification).

(Figure 5), consistent with descriptions in the literature of growth from keratinocytes [14,19]. Thus MD filaments and BDD filaments appear to be similar in formation at the cellular level, both originating from keratinocytes in the stratum spinosum or stratum basale. MD differs from BDD, however, in that MD filaments appear to originate from follicular keratinocytes as well as epidermal keratinocytes. Both MD filaments and BDD filaments fluoresce in UV light (Figures 2-5). We have also shown for the first time that MD filaments contain keratin (Figure 6), and keratin staining was positive using a “pankeratin” monoclonal antibody but negative with a more restricted keratin ligand. This observation indicates that the fibers originate from specific tissues that require further characterization.

The observation that MD fibers are found beneath unbroken skin, may grow from an epidermal matrix and are associated with hair follicles suggests that they are not self-implanted textile fibers [1-3]. The filament formation described in MD is associated with a high

likelihood of Bb infection [1,10]. BDD in cattle is associated with hyperkeratosis, keratin filament formation and spirochetal infection [12-20]. Hyperkeratosis and excessive keratin production associated with chronic inflammation has been demonstrated in humans with cholesteatoma [23,24], and alterations in keratinocyte expression of HLA markers and tissue enzymes have been reported in association with Bb infection [25,26]. These observations suggest that hyperkeratosis and keratin filament production associated with spirochetal infection is a plausible explanation for the clinical and microscopic findings in MD.

Hyaline and colored filaments from the three case studies demonstrate iridescence and an appearance consistent with keratin. Red, blue, purple and black are colors found in keratin and are associated with structural coloring and/or melanin production [27-30]. Clusters of early filaments described in Case 1 demonstrate that fibers are anchored and growing from a basal epithelial cell matrix. They are clearly biological and human in nature and are not implanted textile fibers. Various growth stages of fibers attached to epidermal matrices have been observed. These range from early filaments isolated or in clusters (that are only a few µm in diameter and 10 µm long) to long tangled mats (with fibers 10 µm or wider in diameter and several hundred µm long). Similar filament structures have previously been reported and photographed in MD [31]. Textile fibers have never been produced in this manner, and the suggestion that these unusual formations are manufactured textile fibers is not credible.

Longer fibers with tapered ends anchored to a cellular matrix were observed in Case 1, demonstrating filament evolution. Colored fibers were often found near larger hair follicles or appeared to have follicular bulb-like ends, suggesting an association with hair follicles and follicular keratinocytes. Our chemical studies suggest that MD filaments and BDD fibers react to caustic agents in a manner similar to normal hair, although MD filaments appeared to be more susceptible and BDD fibers less susceptible to the caustic agents Table 1. In preliminary studies using scanning electron microscopy, the presence of scales on a blue filament indicated that this specimen was a fine hair (D’Alba L and Shawkey MD, unpublished observation, December 2011). This finding suggests that some of the colored fibers of follicular origin may in fact be modified hairs. Differences between the keratinocytes found in the inner root sheath of hair follicles and keratinocytes found in the basal skin layer may account for the differences of location, structure, coloring and size of fibers seen in this study [32,33]. The effect of spirochetes on keratinocyte function may also play a role in altered keratin production associated with MD and BDD [22,25,26].

In conclusion, MD lesions were not caused by self-mutilation or delusions in the three cases presented here. The photographic evidence clearly demonstrates that the unusual fibers or filaments described in this study are not self-implanted textile fibers. All three patients had symptoms and laboratory findings consistent with systemic illness and indicative of tickborne disease. Neuropsychiatric testing was normal in two cases and influenced by the disease in the third case, and all three patients were examined by a medical practitioner who confirmed the presence of fibers underneath unbroken skin compatible with a diagnosis of MD.

We have demonstrated that filaments found in MD patients have chemical, physical and immunohistological features of keratin. The presence of individual filaments attached to epithelial tissue is consistent with keratin and suggests that the filaments are produced by keratinocytes. Morgellons filaments have been photographed

growing from pavement epithelial cells, and this process resembles the evolution of filaments seen in BDD. Because BDD is a disease in which spirochetes have been identified as primary etiologic agents, and spirochetal sero-reactivity has been associated with MD, it is reasonable to assume that spirochetal infection plays an important role in MD filament production. Further immunohistological and electron microscopy studies are needed to solve the mystery of Morgellons filaments.

#### Conflict of Interest Statement

RBS serves without compensation on the medical advisory panel for QMedRx Inc. He has no financial ties to the company. MJM, EHR and RBS serve without compensation on the scientific advisory panel of the Charles E. Holman Foundation. DGK has no conflicts to declare.

#### Acknowledgments

The authors thank Drs. Gordon Atkins, Robert Bransfield, Dorte Dopfer, Alan MacDonald, Peter Mayne, Deryck Read, Matthew Shawkey, Janet Sperling, Ginger Savely, Michael Sweeney and Randy Wymore for helpful discussion. We thank Dr. Robert B. Allan for technical support and Lorraine Johnson for manuscript review, and we are grateful to Harriet Bishop, Cindy Casey and Lee Laskowsky for providing first-hand information about Morgellons disease.

#### References

- Savely VR, Leitao MM, Stricker RB (2006) The mystery of Morgellons disease: infection or delusion? *Am J Clin Dermatol* 7: 1-5.
- Savely VR, Leitao MM (2005) Skin lesions and crawling sensations: disease or delusion? *Adv Nurse Pract* 13: 16-17.
- Middelveen MJ, Stricker RB (2011) Filament formation associated with spirochetal infection: A comparative approach to Morgellons disease. *Clin Cosmet Investig Dermatol* 4: 167-177.
- Elkan D. Morgellons (2007) disease the itch that won't be scratched. *New Scientist* 2621: 46-49.
- Wymore RS (2011) Morgellons disease research; shotgun DNA analysis, PCR, microscopy and spectroscopy. Morgellons Medical Conference, Austin, Texas.
- Pearson ML, Selby JV, Katz KA, Cantrell V, Braden CR, et al. (2012) Clinical, epidemiologic, histopathologic and molecular features of an unexplained dermopathy. *PLoS ONE* 7: e29908.
- Savely VR, Stricker RB (2007) Morgellons disease: the mystery unfolds. *Expert Rev Dermatol* 2: 585-591.
- Harvey WT (2007) Morgellons disease. *J Am Acad Dermatol* 56: 705-706.
- Harvey WT, Bransfield RC, Mercer DE, Wright AJ, Ricchi RM, et al. Morgellons disease, illuminating an undefined illness: a case series. *J Med Case Reports* 3: 8243.
- Savely VR, Stricker RB (2009) Morgellons disease: analysis of a population with clinically confirmed microscopic subcutaneous fibers of unknown etiology. *Clin Cosmet Investig Dermatol* 3: 67-78.
- Cheli R, Mortellaro CM (1974) Digital dermatitis in cattle. *Proc 8<sup>th</sup> Int Meet Dis Cattle, Milan, Italy* 8: 208-213.
- Vink WD, Jones G, Johnson WO, Brown J, Demirkan I, et al. (2009) Diagnostic assessment without cut-offs: application of serology for the modeling of bovine digital dermatitis infection. *Prev Vet Med* 92: 235-248.
- Dopfer D, Willemann MA (1998) Standardisation of infectious claw diseases. *Proceedings of the 10<sup>th</sup> International Symposium on Lameness in Ruminants; Lucerne, Switzerland* 244-254.
- Borgmann JE, Bailey J, Clark EG (1996) Spirochete-associated bovine digital dermatitis. *Can Vet J* 37: 35-37.
- Blowey RW, Sharp MW (1988) Digital dermatitis in dairy cattle. *Vet Rec* 122: 505-508.
- Read DH, Walker RL, Castro AE, Sundberg JP, Thurmond MC (1992) An invasive spirochaete associated with interdigital papillomatosis of dairy cattle. *Vet Rec* 130: 59-60.
- Scavia G, Sironi G, Mortellaro CM, Romusi S (1994) Digital dermatitis: further contribution on clinical and pathological aspects in some herds in northern Italy. *Proc Int Symp Dis Ruminant Digit* 8: 174-176.
- Grund S, Nattermann H, Horsch F (1995) Electron microscopic detection of spirochetes in dermatitis digitalis of cattle. *Zentralbl Veterinarmed B* 42: 533-542.
- Döpfer D, Koopmans A, Meijer FA, Szakáll I, Schukken YH et al. (1997) Histological and bacteriological evaluation of digital dermatitis in cattle, with special reference to spirochaetes and *Campylobacter faecalis*. *Vet Rec* 140: 620-623.
- Demirkan I, Carter SD, Murray RD, Blowey RW, Woodward MJ (1998) The frequent detection of a treponeme in bovine digital dermatitis by immunohistochemistry and polymerase chain reaction. *Vet Microbiol* 60: 285-292.
- Read DH, Walker RL (1998) Papillomatous digital dermatitis (footwarts) in California dairy cattle: clinical and gross pathologic findings. *J Vet Diagn Invest* 10: 67-76.
- Gomez A, Cook N, Dopfer D, Bernardoni N, Dusick A, et al. (2011) An experimental infection model for digital dermatitis. *Lameness in Ruminants Conference, New Zealand*.
- Hamajima Y, Komori M, Preciado DA, Choo DI, Morobe K et al. (2010) The role of inhibitor of DNA-binding (ID1) in hyperproliferation of keratinocytes: the pathological basis for middle ear cholesteatoma from chronic otitis media. *Cell Prolif* 43: 457-463.
- Raynov AM, Choung YH, Park HY, Choi SJ, Park K (2004) Establishment and characterization of an in vitro model for cholesteatoma. *Clin Exp Otorhinolaryngol* 1: 86-91.
- Tjernlund U, Scheynius A, Asbrink E, Hovmark A (1986) Expression of HLA-DQ antigens on keratinocytes in *Borrelia* spirochete-induced skin lesions. *Scand J Immunol* 23: 383-388.
- Gebbia JA, Coleman JL, Benach JL (2001) *Borrelia* spirochetes upregulate release and activation of matrix metalloproteinase gelatinase B (MMP-9) and collagenase 1 (MMP-1) in human cells. *Infect Immun* 69: 456-462.
- Shawkey MD, Hill GE (2005) Carotenoids need structural colors to shine. *Biol Lett* 1: 121-124.
- Shawkey MD, Shree Kumar RP, Hill GE, Siefferman LM, Roberts SR (2007) Bacteria as an agent for change in structural plumage color: correlational and experimental evidence. *Am Nat* 169: S112-S121.
- D'Alba L, Saranathan V, Clarke JA, Vinther JA, Prum RO, et al. (2011) Colour-producing  $\beta$ -keratin nanofibres in blue penguin (*Eudyptula minor*) feathers. *Biol Lett* 7: 543-546.
- Chung WJ, Oh JW, Kwak K, Lee BY, Meyer J, et al. (2011) Biomimetic self-templating supramolecular structures. *Nature* 478: 364-368.
- Charles E. Holman Foundation (2012) Accessed February 16.
- Rugg EL, Leigh IM (2004) The keratins and their disorders. *Am J Med Genet C Semin Med Genet* 131C: 4-11.
- Moll R, Divo M, Langbein L (2008) The human keratins: biology and pathology. *Histochem Cell Biol* 129: 705-733.

#### Submit your next manuscript and get advantages of OMICS Group submissions

##### Unique features:

- User friendly/feasible website-translation of your paper to 50 world's leading languages
- Audio Version of published paper
- Digital articles to share and explore

##### Special features:

- 200 Open Access Journals
- 15,000 editorial team
- 21 days rapid review process
- Quality and quick editorial, review and publication processing
- Indexing at PubMed (partial), Scopus, DOAJ, EBSCO, Index Copernicus and Google Scholar etc
- Sharing Option: Social Networking Enabled
- Authors, Reviewers and Editors rewarded with online Scientific Credits
- Better discount for your subsequent articles

Submit your manuscript at: [www.editorialmanager.com/clinicalgroup](http://www.editorialmanager.com/clinicalgroup)